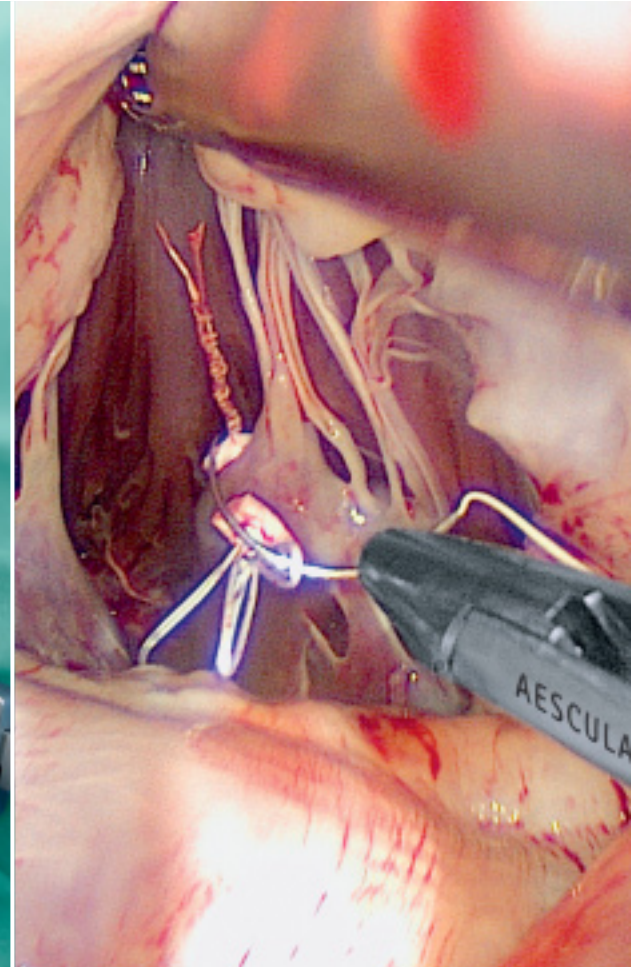
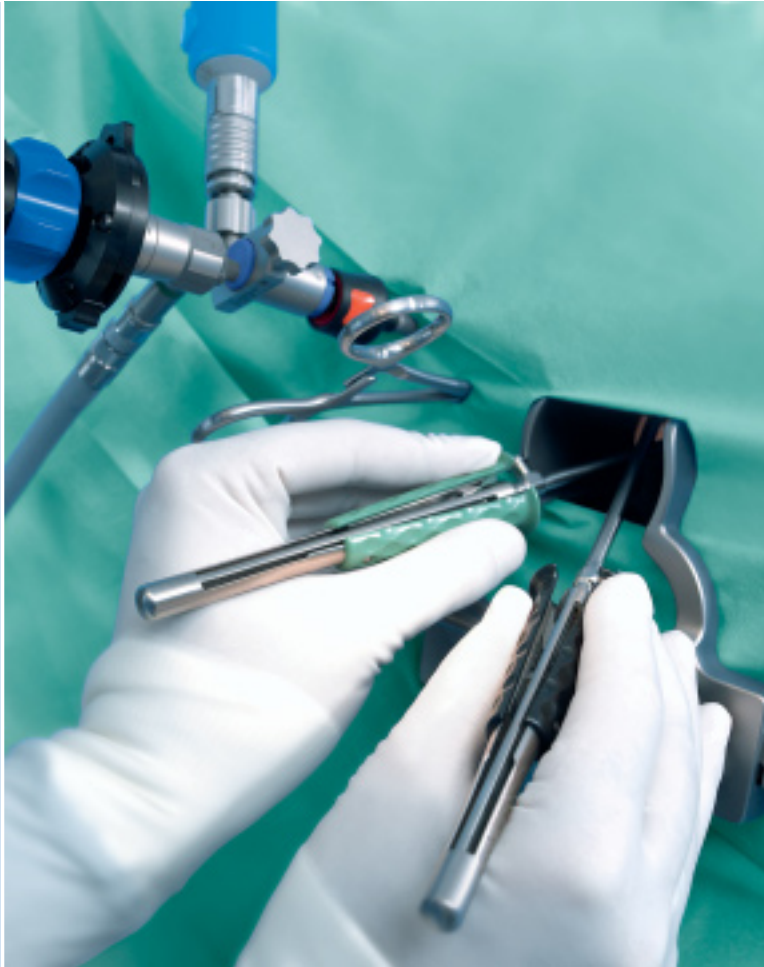

# Valve XS

Operation Manual for Minimally Invasive Mitral Valve Repair

Stephan Jacobs

Department of Cardiovascular Surgery, University of Zurich, Switzerland



Aesculap Surgical Technologies

**AESCULAP**<sup>®</sup>



# Valve XS

## Operation Manual for Minimally Invasive Mitral Valve Repair

---

Volkmar Falk, MD, PhD  
Department of Cardiovascular Surgery,  
University of Zurich, Switzerland

Stephan Jacobs, MD, PhD  
Department of Cardiovascular Surgery,  
University of Zurich, Switzerland

Rämistrasse 100  
8091 Zurich, Switzerland  
Fax: +41-44-255-2303  
Phone: +41-44-255-4446  
E-mail: [stephan.jacobs@usz.ch](mailto:stephan.jacobs@usz.ch)

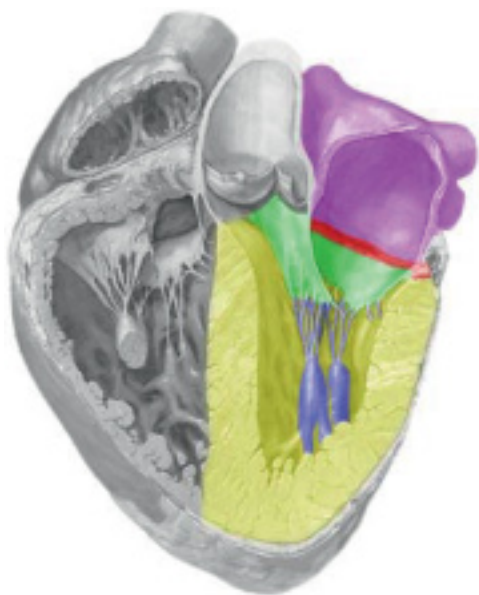
# Valve XS

## Operation Manual for Minimally Invasive Mitral Valve Repair

### Introduction

Mitral valve (MV) repair is the gold standard for the treatment of mitral regurgitation (MR)[1–5] today. There is currently no reasonable alternative to surgery which can be curative and result in the prevention of subsequent heart failure [6, 7]. Mitral valve repair has been conclusively demonstrated to be superior to MV replacement with improved post-operative survival rates and preserved left ventricular function. Modern cardiac surgery programs with a high volume number have achieved very high MV repair rates with minimal peri-operative mortality and long-term outcomes that are comparable with the general population. [1–5, 8, 9]

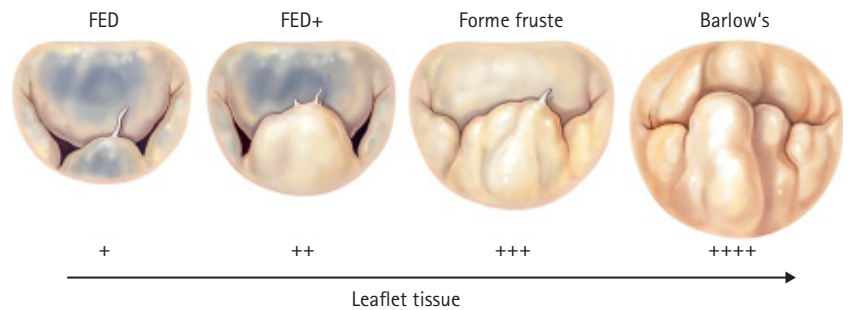
The Mitral valve is a highly complex structure based upon five different components (Figure 1): the mitral annulus, the anterior and posterior leaflet, the chordae tendinae, the papillary muscles, and the left ventricle. An exceptionally complex mechanism underlies the systolic and diastolic function of the MV. Even today, the complete task and function of the MV is not fully understood and continues to be the subject of a tremendous amount of research activities. Detailed pathophysiological mechanisms regarding the two highest prevalence entities—degenerative and functional MR remain uncertain. The goal of a mitral valve repair procedure for degenerative disease follows two fundamental principles: restore a good surface of leaflet coaptation and correct for annular dilatation [1, 10]. A leaflet coaptation line of 5–8 mm is considered essential to provide a durable repair result.



**Figure 1:** Purple: left atrium (LA); red line: mitral annulus; green: anterior and posterior leaflet; blue: chordae and papillary muscle

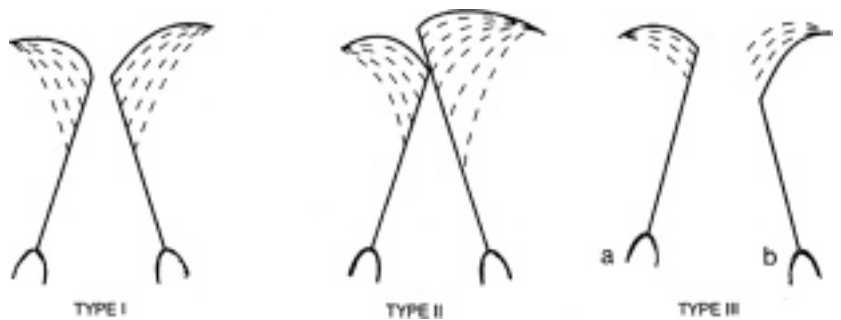## Pathology of mitral valve disease

Degenerative mitral valve disease is a common disorder affecting around 2% of the population [6]. The most common finding in patients with degenerative valve disease is leaflet prolapse due to elongation or rupture of the chordal apparatus, resulting in varying degrees of mitral valve regurgitation due to leaflet malcoaptation during ventricular contraction (Figure 2). The emphasis of clinical decision-making in patients with degenerative disease centers around the severity of regurgitation and its impact on symptom status, ventricular function and dimension, the sequelae of systolic flow reversal such as atrial dilatation/fibrillation and secondary pulmonary hypertension, and the risk of sudden death [1, 11, 12].



**Figure 2:** Spectrum of degenerative mitral disease ranging from fibroelastic deficiency (FED) to Barlow's disease

Functional MR arises as a consequence of left ventricular dilatation with or without leaflet tethering due to either ischaemic or dilatative cardiomyopathy [6, 15]. The most commonly used classification of MV dysfunction and MR has been introduced by Carpentier, consisting of types I–IIIb (Figure 3) and have been extensively described elsewhere [6, 14, 15].



**Figure 3:** Type I: normal leaflet motion; Type II: leaflet prolapse; Type III: restricted leaflet motion a.) diastolic b.) systolic (ICM, DCM)

# Valve XS

## Operation Manual for Minimally Invasive Mitral Valve Repair

---

### **Timing of surgical intervention**

Controversy exists as to whether early surgical intervention in asymptomatic patients, before the onset of ventricular changes, improves the outcome of patients with chronic severe degenerative mitral valve disease [1,13]. This debate has put emphasis on the lack of predictability of mitral valve repair, despite broad consensus that this is the procedure of choice for patients undergoing surgical intervention. The confidence gap in predicting successful mitral valve repair is one of the factors responsible for the lack of adherence to guidelines directed toward timely referral of patients with indications for surgery. An emerging accord is building that current medical and surgical practice often results in suboptimal care for the individual patient with degenerative mitral valve disease, and indeed a paradigm shift or 'revolution' through education is not only predictable but essential to advance the field. All practicing cardiovascular specialists should have familiarity with the 'state of art' in terms of degenerative disease differentiation, timing of intervention, and surgical techniques and results in order to improve patient care [7].

### **Principles for mitral valve repair**

Three principle goals of MV repair were introduced by Carpentier: Stabilization of the annulus with the retention of an adequately sized mitral orifice, restoration of physiological leaflet motion and recreation of a sufficient line of coaptation [10]. Specific techniques such as ring annuloplasty, resection of leaflet prolapse, leaflet sliding plasty, and others have been ascribed to Carpentier and are together known as the 'French correction.' These 'classical' repair techniques have proved excellent results with a high durability and high freedom from reoperation rate [1–5, 8, 9]. Numerous additional repair techniques such as implantation of neo chordae, edge-to-edge repair, papillary muscle shortening, leaflet reduction plasty, and others have been developed, affording the surgeon a wide armamentarium of approaches [1–5, 16–22]. For patients with degenerative MV disease, a surgical repair rate of nearly 100% has been reported in select reference centers [8]. Simultaneously, peri-operative mortality and morbidity rates for complications such as stroke and valve-related reoperation have been excellent, occurring in 2% of patients. It has also been recently shown that even the historically more difficult repair of anterior or bileaflet mitral prolapse can be achieved in 90% of patients, with long-term survival and freedom from reoperation rates that are similar to the more straight forward isolated posterior prolapse pathology [2, 4].

---

These superb results can also be achieved through a minimally invasive technique leading to a better cosmetic result, a decreased incidence of respiratory failure, decreased post-operative pain, and a faster recovery [4, 8, 9, 23]. For patients with functional MR, undersized mitral annuloplasty is the current surgical gold standard. This strategy attempts to reshape the mitral annulus to a more anatomically correct form, thus leading to increased leaflet coaptation and a competent MV. It is of utmost importance for this operation that a complete rigid annuloplasty ring is implanted, rather than an open flexible band [24, 25]. Undersized annuloplasty has been associated with left ventricular reverse remodeling and improvement of symptoms in the majority of patients, but recurrent MR occurs more frequently than in patients with degenerative disease. Recently developed strategies such as the 'ring and string' concept, secondary chordal cutting, septal-lateral banding, and posterior leaflet extension have been suggested as additional techniques that may minimize the risk of recurrent MR [26–28]. Current surgical MV repair offers a highly effective and safe treatment for patients with MR, even in those patients who require reoperative procedures [1–5, 8, 9, 23, 29]. Most important, however, is the fact that surgery frequently results in a complete correction of the MR and normalization of valve morphology, and thus represents the only curative treatment strategy for patients with MR. The high mountain of surgical MV repair therefore represents the current gold standard for the treatment of MR.

# Valve XS

## Surgical Procedure – Step by Step

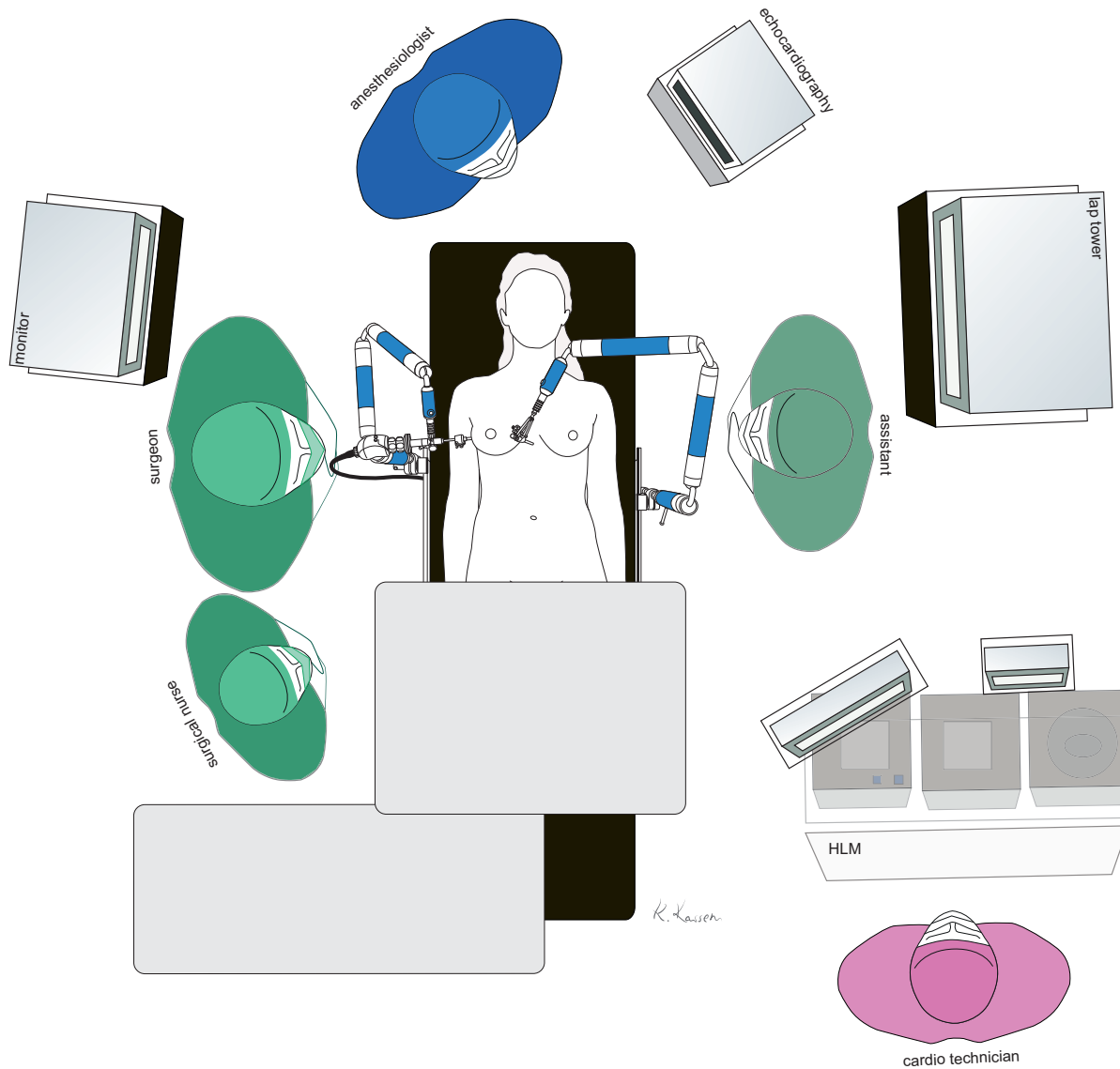


Figure 4: OP Setting

The right groin is favored for cardio pulmonary bypass cannulation due to anatomical reasons, since it allows easier venous cannulation. Thus in case of a preoperative angiogram for exclusion of any relevant coronary artery vessel disease, the left groin should be used for access.

Intraoperative set-up including anesthesiologist, surgeon, surgical assistant, scrub nurse and perfusionist, in a standard fashion (Figure 4). Two monitors for endoscopic view are recommended, one each for the leading surgeon and the surgical assistant.



Standard monitoring for cardiac surgery is used. A central and arterial line is placed and defibrillator pads are placed on the back towards the right chest (as laterally as possible). A double-lumen endotracheal tube can be helpful but is basically unnecessary. For selection of the most appropriate repair technique a complete understanding of the underlying degenerative etiology, anatomical lesions, and leaflet dysfunction (excess or restricted leaflet motion) is mandatory. Intraoperative transesophageal 2D and, increasingly used, real time 3D transesophageal echocardiography (TEE) is performed to guide the procedure and finally confirm the postoperative result.

In case of tricuspid valve surgery, the right superior vena cava (SVC) must be cannulated for venous drainage of the upper body (Figure 5).

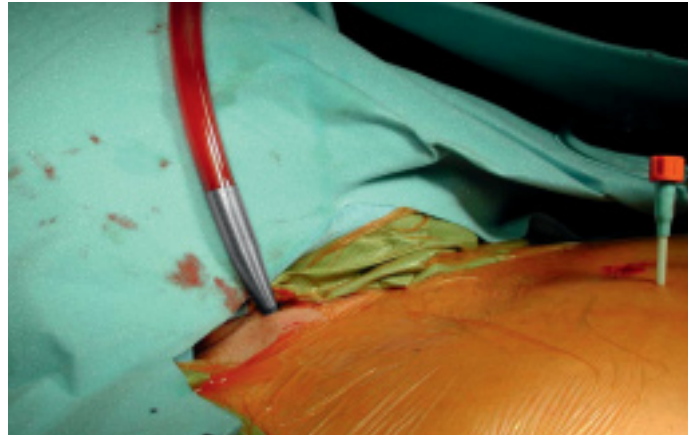


Figure 5: SVC cannulation

The patient is placed in a supine position with a positioning roll placed caudal to the right scapula parallel to the spine in order to lift the right thorax up in an angle of 35 to 45°. The patient is then draped in a way to allow for right lateral minithoracotomy, and in case of an emergency for standard full median sternotomy. The lower axillary line must be accessible for placement of the transthoracic aortic clamp.

Two holding arms (Unitrac RT040R), one for the endoscope and one for the left atrium retractor, are mounted on the OR table rail on each side at the level of the patients head. The operating table is rotated 10° to 15° to raise the patient's right side. Final patient positioning should allow for easy access to the right chest and right groin (Figure 6).




Figure 6: Positioning of the patient

After administration of the heparin, cardiopulmonary bypass is instituted via femoral arterial and venous cannulation through a 3- to 4-cm oblique incision in the right groin (Figure 7).




Figure 7: Cannulation for extra corporal bypass

# Valve XS

## Surgical Procedure – Step by Step



Figure 8: Right lateral thoracotomy in the fourth intercostal space.



Figure 9: Soft tissue retractor



Figure 10: Stay suture for diaphragm

The tip of the venous cannula is positioned under transesophageal echocardiographic guidance at the junction of the inferior cava and the right atrium. Mild hypothermia (34 °C) and vacuum-assisted venous drainage is applied. After the extracorporeal circulation has been instituted, adequate exposure of the right and left atrium and thus the mitral valve (MV) is mandatory by termination of ventilation with disconnection of the endotracheal tube. A four to five centimeter incision in the fourth intercostal space gives access to the intra-thoracic cavity (Figure 8).

As the next step, a soft tissue retractor is introduced (Figure 9).

After the mini-thoracotomy, it is mandatory to scan the thoracic cavity for adhesions in order to safely install additional ports, the camera, atrial retractor and aortic clamp. In case of an elevated diaphragm, which inhibits direct vision to the left atrium, a stay suture is recommended to bring the diaphragm "down" (Figure 10).

In case of a limited surgical field, the thoracic retractor can be introduced, but it is not prerequisite (Figure 11).

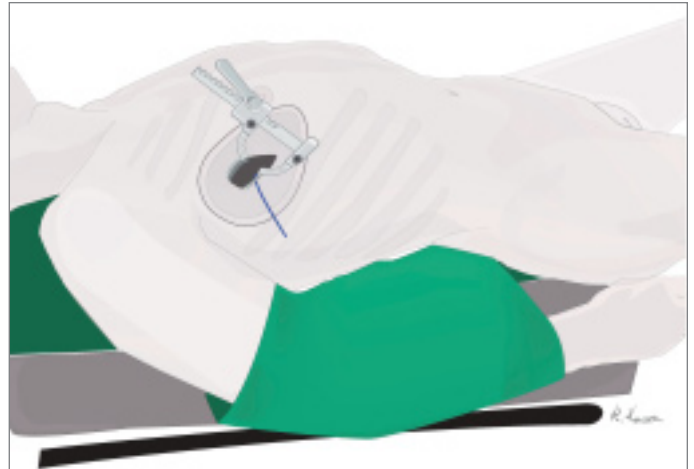


Figure 11: Thoracic retractor

The camera port is placed in the second intercostal space lateral to mid-clavicular line followed by insertion of the camera. In addition, CO<sub>2</sub>-insufflation is initiated to improve de-airing at the end of procedure. Then the transthoracic "Chitwood" clamp is used for cross clamping of the aorta. The clamp is introduced through an extra incision medial to anterior axillary line (Figure 12).

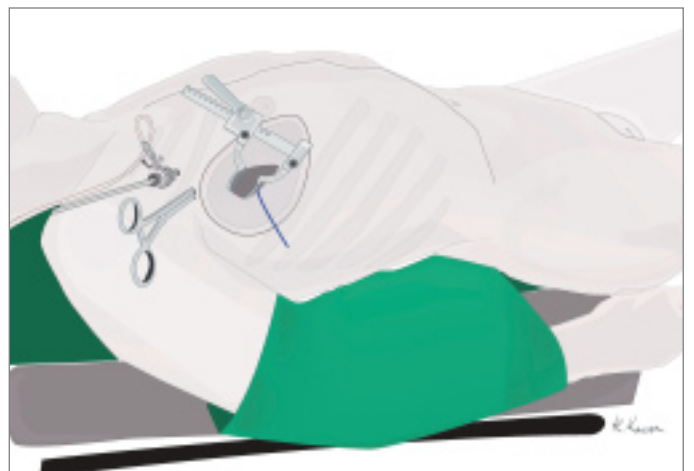

Figure 12: Position of camera port and "Chitwood" clamp

To ensure an optimal surgical exposition it is recommended to dissect the adjacent pericardial fatty tissue (Figure 13).

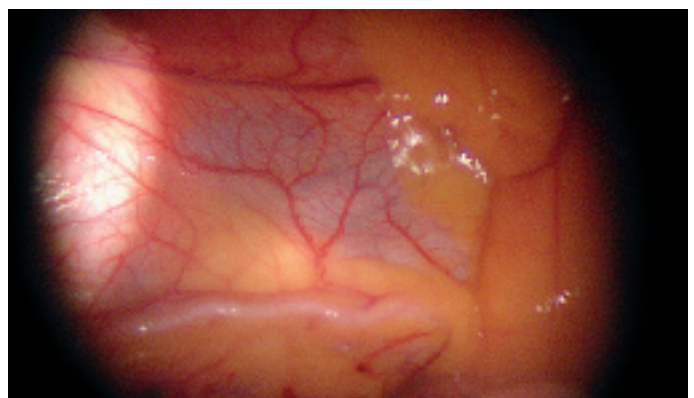


Figure 13: Phrenic nerve and pericardial fat tissue

# Valve XS

## Surgical Procedure – Step by Step

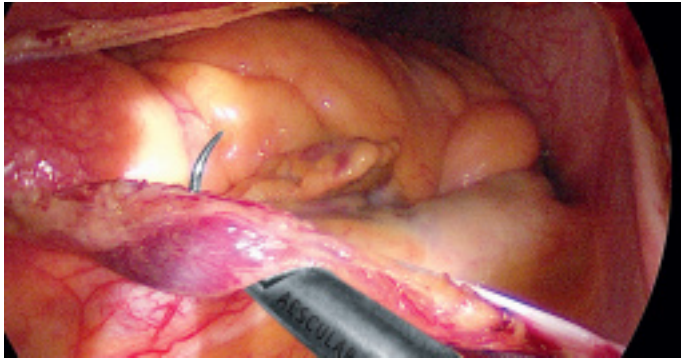


Figure 14: Placement of pericardial retraction sutures

The pericardiotomy is performed with a longitudinal incision of the pericardium approximately three to four centimeters parallel to the phrenic nerve. Two stay sutures can be placed close to the phrenic nerve for retraction in order to improve exposition and clear visualization of the left atrium (LA) (Figure 14).

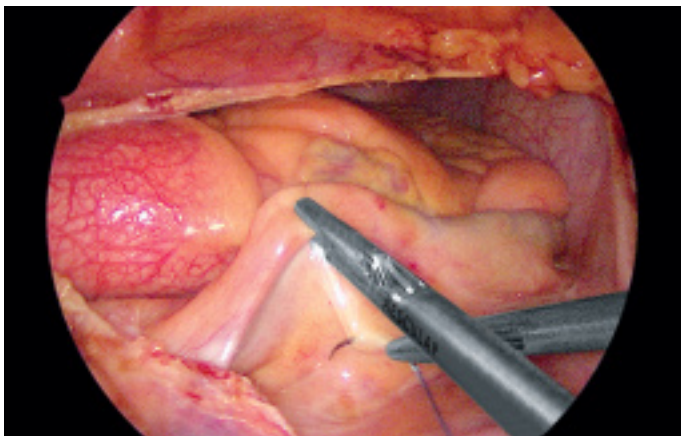


Figure 15: Placement of the LA suture for better visualization

A retraction suture is placed into the inter-atrial groove to lift up the left atrium (Figure 15). Identification of the best spot is facilitated by identifying anatomical landmarks.

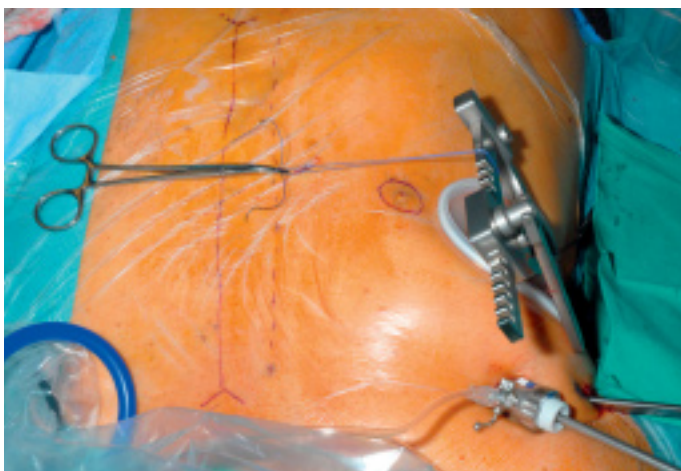


Figure 16: Anatomical orientation to guide placement of LA retraction suture

For better orientation the suture can be aligned outside the chest wall (Figure 16), the continuous line marks the sternum and the dotted line identifies the right internal thoracic artery (ITA).

The ideal site for the execution of the suture can be determined by the dotted line, which reminds a safety gap to avoid any injury of the ITA. The suture is easily pulled through using a clamp (Figure 17).

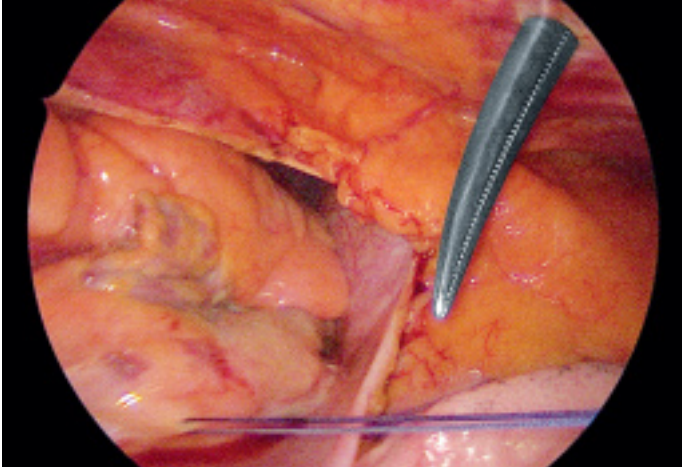


Figure 17: Placement of the retraction suture

With blunt dissection, the LA can be separated from the inferior vena cava (IVC, Figure 18).

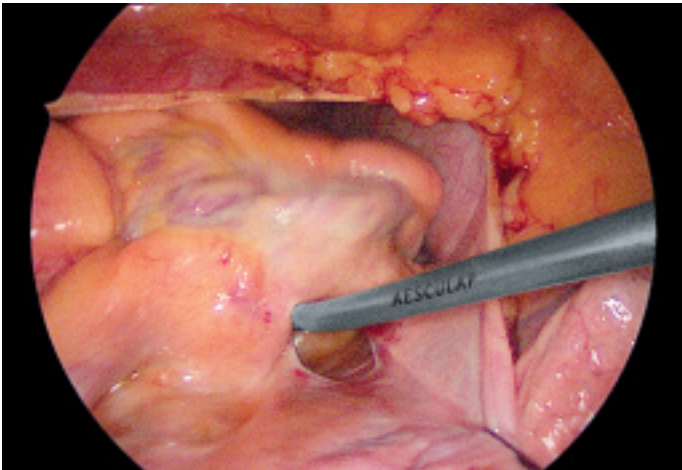


Figure 18: Blunt dissection of LA an IVC

The transthoracic aortic clamp can be introduced medial to the anterior axillary line in the second ICS (Figure 19). Care has to be taken to avoid damaging the pulmonary artery and/or the left atrial appendage (LAA) when closing the Chitwood clamp. As a hint, the aortic occlusion is best performed by pushing the LAA aside with the suction device. The convex side of the clamp is supposed to face toward the head of the patient.

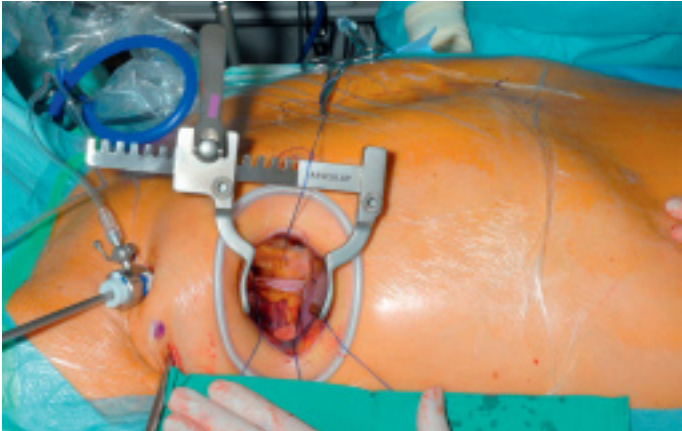


Figure 19: Intraoperative set-up immediately after aortic cross clamping

# Valve XS

## Surgical Procedure – Step by Step

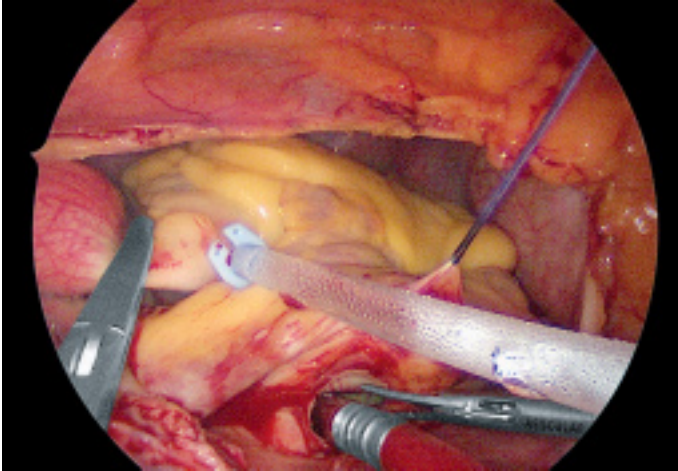


Figure 20: Application of 2000 ml crystalloid cardioplegia as a single shot

Crystalloid Bretschneider cardioplegia (2000 ml) is administered antegrade directly into the aortic root over a commercially available modified needle-vent. In case of aortic occlusion of more than 90 minutes this procedure can be repeated. While applying the cardioplegia the LA is incised (Figure 20).

The LA incision is extended to allow for a suitable access to the MV. It can be opened as far as 1 cm to the SVC and midway between the right inferior pulmonary vein and the IVC. The surgical field is flooded throughout the operation with carbon dioxide and a left atrial vent is placed to drain the pulmonary venous return.

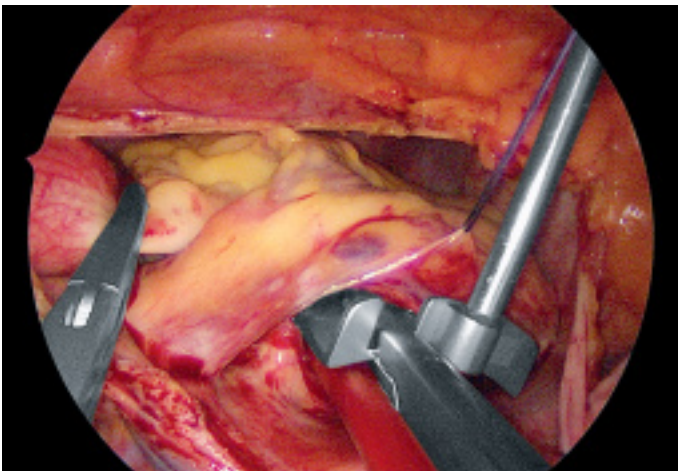


Figure 21: Introduction of the left atrial roof retractor

Maximal exposure of the MV is obtained using an atrial roof retractor. The size of the roof blade needs to be chosen according to the size of the LA. If the exposure remains sub-optimal, then the LA incision can be enlarged and/or another intercostal space is selected (Figure 21).

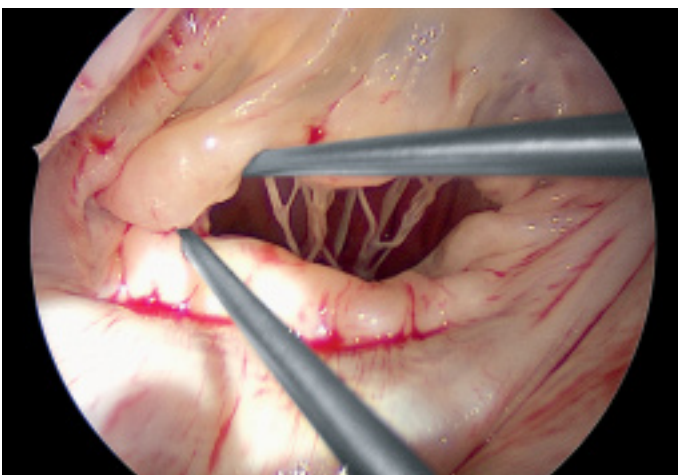


Figure 22: Analysis of valve morphology using nerve hooks

The goal of MV analysis is to confirm or modify the planned repair strategy based on the preoperative echocardiography. This includes selection of functional type and identification of morphology, such as segmental location and others. The leaflets are examined with two nerve hooks to allow comprehensive analysis of all leaflet segments and subvalvular apparatus. Valve analysis is carried out in an organized manner using P1 as a reference point in most instances (Figure 22). Whenever P1 motion and / or morphology are abnormal, another segment needs to be identified to serve as the reference point.

In this case, a large P2 prolapse is obvious due to chordae rupture (Figure 23). With regards to repair strategy, any leaflet pathology should be corrected in first place, followed by annuloplasty using complete ring implantation. For better exposure and visualization of the subvalvular apparatus, the anterior leaflet can be gently retracted by loading the leaflet onto the blade of the atrial roof retractor.

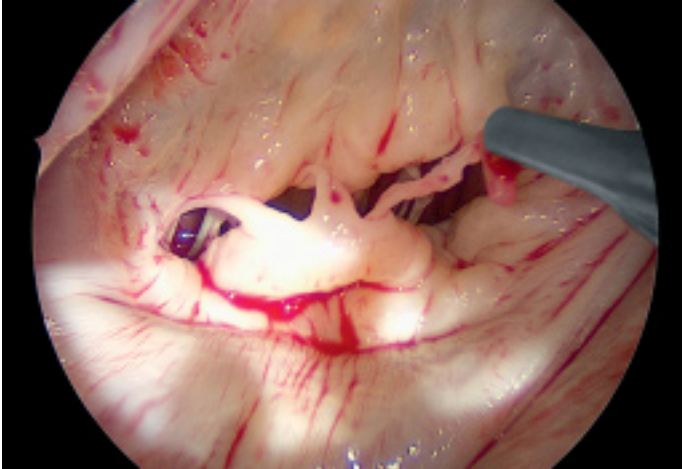


Figure 23: P2 prolapse due to chordae rupture

To restore the P2 prolapse, the loop technique, using 4 pre-made PTFE (5/0 sutures with four loops of identical length), is a favorable repair technique. The length of required loops is determined by measuring the appropriate distance from the body of the papillary muscle to the free edge of a non-prolapsing portion of the MV leaflet using a custom made caliper FC357R (Figure 24).

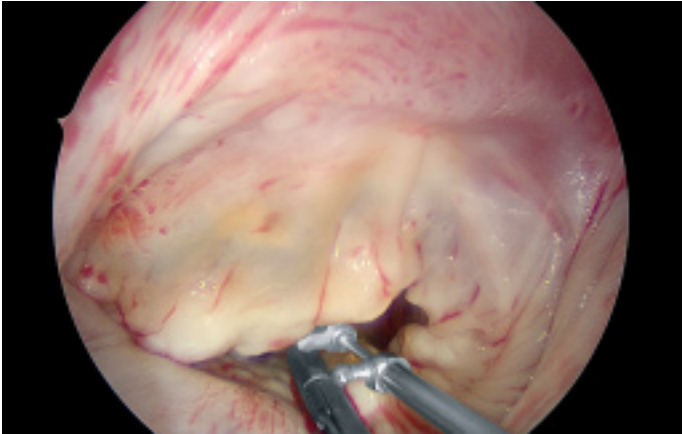


Figure 24: Measurement of the length of the artificial chords

# Valve XS

## Surgical Procedure – Step by Step

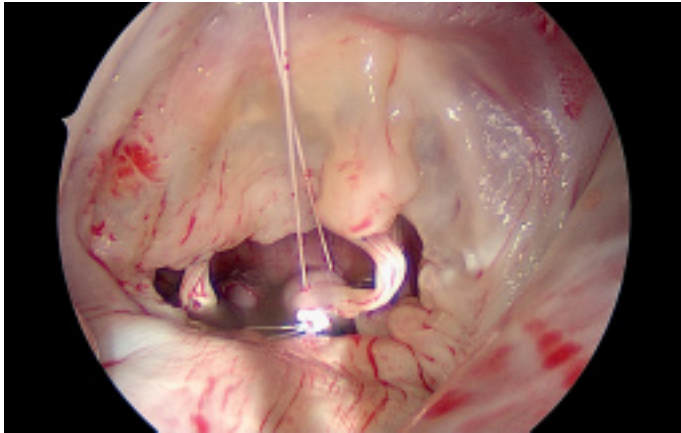


Figure 25: Fixation of artificial chords at the head of the papillary muscle

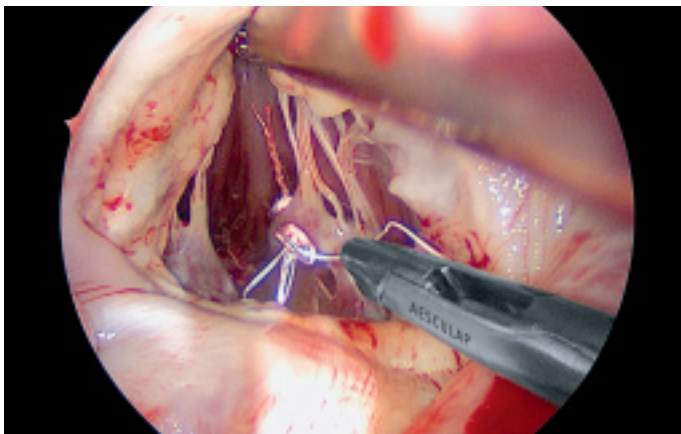


Figure 26: Connection of the artificial loops with 5/0 PTFE suture

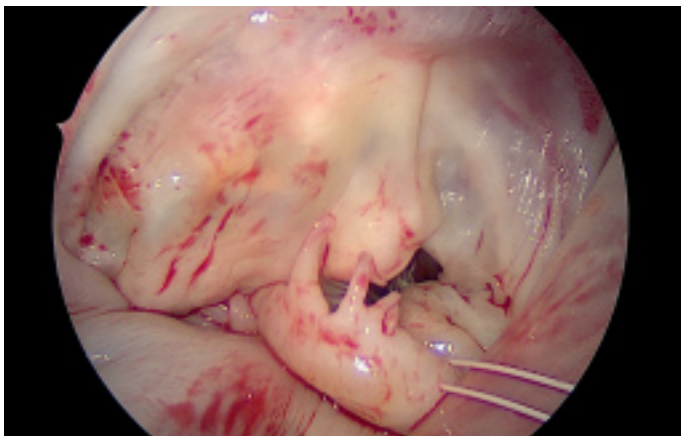


Figure 27: Fixation of artificial loops at the free margin of the leaflet

The loops are commercially available (Santec Medical, Grosswallstadt, Germany) or can be manufactured in-house by a dedicated individual using a single 5/0 PTFE suture. A so-called "loop" consists of a central pledget with four premade single loops, ranging from 10 to 26 mm in length. The needles of the sutures originating from the pledget are then passed through the tip of the respective papillary muscle and tied over a second pledget. The free loops are fixed to the prolapsing leaflet segment using additional 5/0 PTFE sutures, placing the knot on the ventricular surface of the leaflet whenever possible (Figure 25 to 27).



The saline probe confirms successful (or unsuccessful) repair of the mitral valve (Figure 28). For restoring and remodeling the shape of the annulus, a prosthetic ring is implanted. Regardless of the type of ring, ring selection is based on the measurement of the anterior leaflet, first with regards to the basal portion (trigone to trigone), then with regards to the anterior-posterior diameter of the anterior leaflet height (Figure 29).

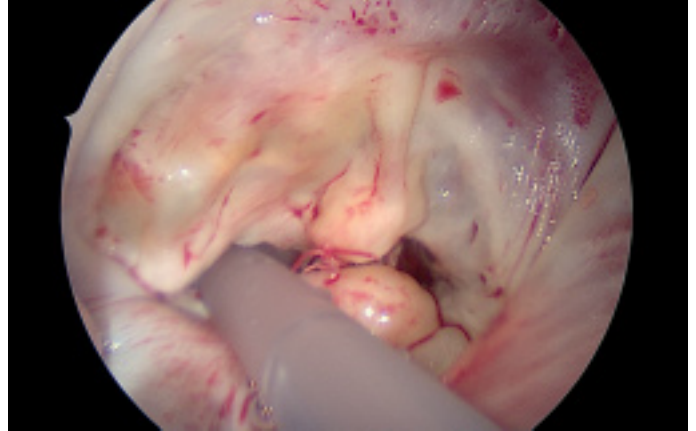


Figure 28: Saline probe

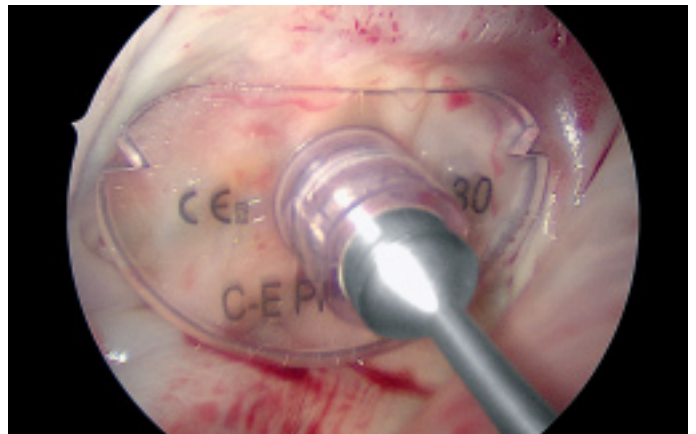


Figure 29: Measurement of annuloplasty ring size under direct vision

Ring implantation is achieved by placing a series of 12 to 15 standard sized 2-0 Premicon mattress sutures through the mitral annulus (Figure 30).

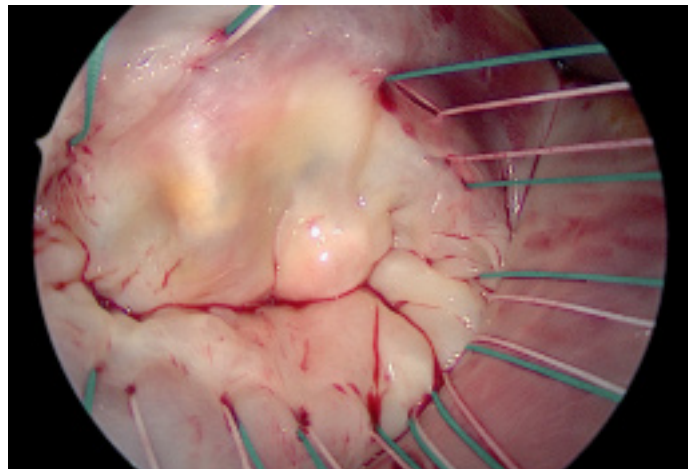


Figure 30: Placement of annuloplasty ring sutures within the annulus

# Valve XS

## Surgical Procedure – Step by Step

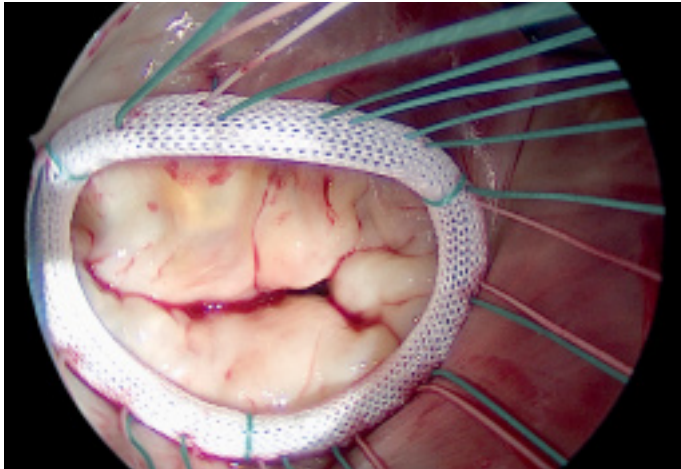


Figure 31: Fixation of annuloplasty ring

The two key factors for the success of ring annuloplasty are (1) proper placement of the sutures within the annulus fibrosus to avoid ring dehiscence and (2) accurate placement of the sutures into the prosthetic ring to avoid annular distortion (Figure 31).

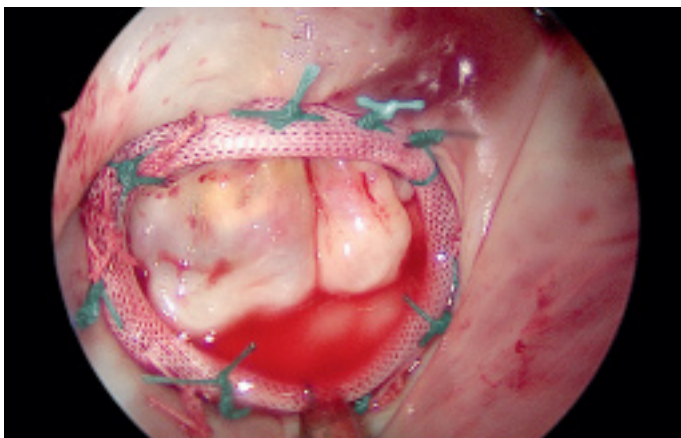


Figure 32: Competent restored mitral valve with saline probe

At the end of the repair the final saline probe confirms a successful procedure. The MV should then "smile" at you (Figure 32).

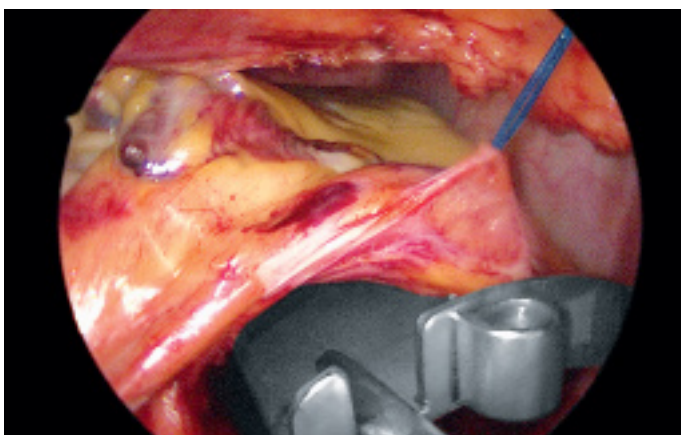


Figure 33: Release of atrial roof retractor

The atrial roof retractor is released and the left atrium is closed with standard 3-0 Premilene suture (Figure 33 and 34). Deairing is performed by completely filling the heart while simultaneously inflating both lungs. During this maneuver it is recommended to retrieve the camera and the pericardial retracting suture to allow for complete de-airing.

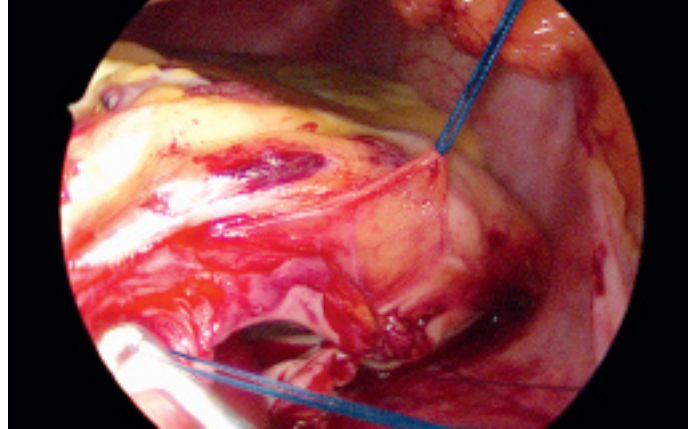


Figure 34: Left atrium closure with 3-0 Premilene and de-airing

After closure of the left atrium, CO<sub>2</sub> insufflation is terminated. In case tricuspid valve repair is planned, silastic tapes or large "bull dog" clamps can be placed around the SVC and IVC. Then beating heart annuloplasty ring implantation on the tricuspid valve can be conducted. Before de-clamping the aorta, a pacemaker wire is placed at the right ventricle (Figure 35). Since the arrested heart allows for enough operative space, a beating heart would highly limit the access to the right ventricular wall.

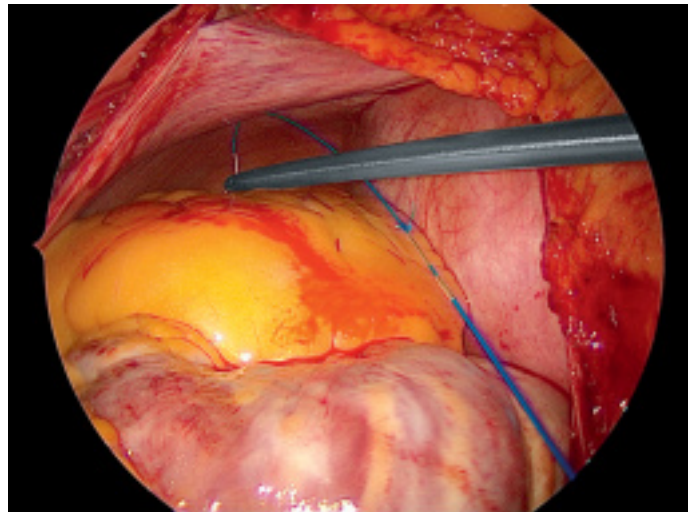


Figure 35: Placement of pacemaker wire

Subsequently the aortic root vent is released and the purse string suture is closed (Figure 36). Then the aortic root clamp is released and the patient rewarmed. Ventilation is started again and the extra corporal bypass is reduced to 50% flow. Transesophageal echocardiogram determines the immediate success of the procedure. To exclude impairment of the circumflex artery, lateral wall motion should be monitored instantly and needs to achieve a comparable level as seen preoperatively. In addition, flow in the circumflex artery should be verified.

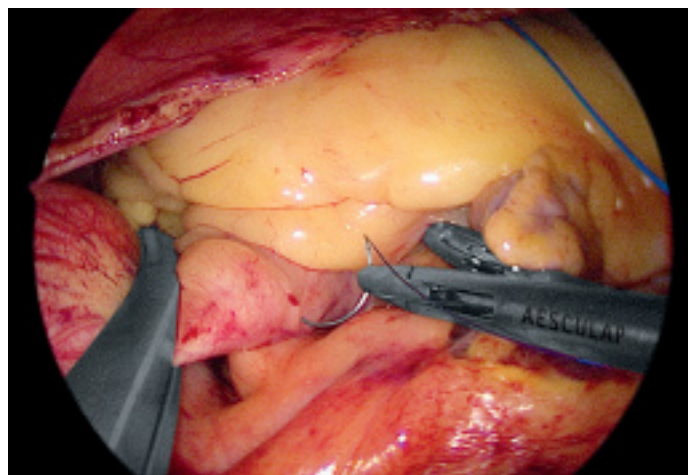


Figure 36: Closure of needle vent puncture with 4-0 Premilene

# Valve XS

## Surgical Procedure – Step by Step

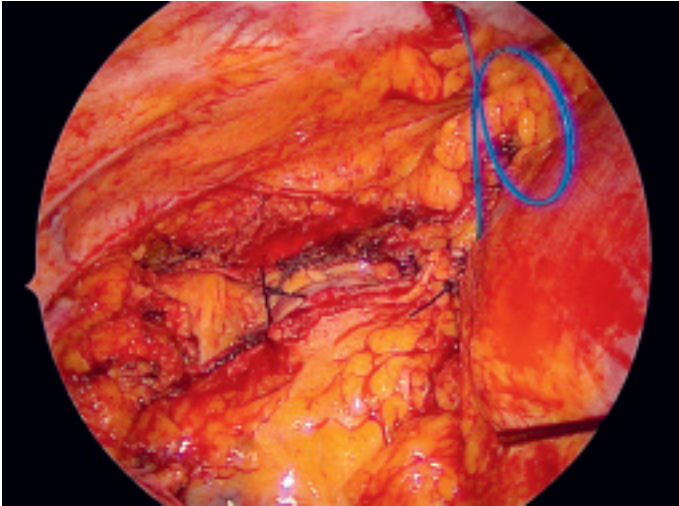


Figure 37: Pericardial closure

When extra corporal bypass flow returns to 100%, ventilation is stopped to allow for access to the heart again. After careful inspection of the suture lines, the pericardium is closed using the pericardial retraction sutures (Figure 37).

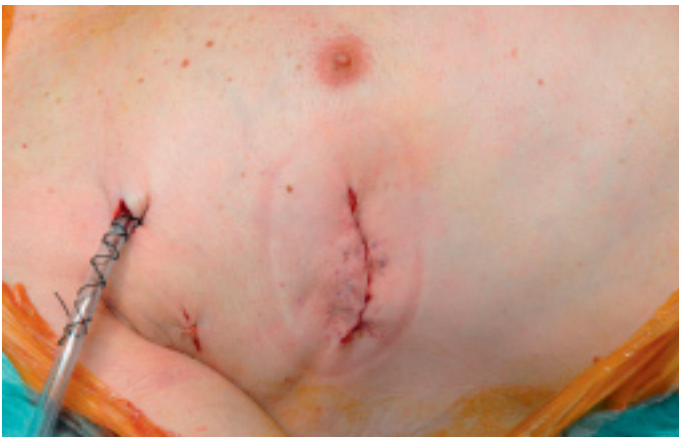

Figure 38: End of procedure

After drainage of potential pleural effusion under direct vision, both lungs are ventilated. A chest tube is inserted through the initial camera port, any other access ports are closed and protamine is given. Extra corporal weaning is followed by closure of the intercostal space and the lateral thoracotomy (Figure 38).

All patients undergoing mitral valve repair should have a post-repair intraoperative transesophageal echocardiogram to determine the immediate success of the procedure [30]. A finding of a more than mild mitral regurgitation should lead the surgeon, except in certain high-risk patients, to perform valve re-exploration to identify and correct any the source of potential *residual* regurgitation.

## Summary

---

Traditionally, mitral valve repair procedures have been performed through a 15–20 cm skin incision and full median sternotomy. The less invasive approach via right-sided, mini-thoracotomy with video assistance and femoral cannulation for cardiopulmonary bypass is now successfully performed in many expert centers [31]. The minimally invasive technique has achieved results that are comparable with the standard conventional approach via a complete sternotomy. A high rate of repair can be achieved in MR patients undergoing minimal invasive mitral valve surgery with low rates of perioperative morbidity and mortality [9, 23].

Early echocardiographic findings and mid-term valve reoperation rates are very encouraging.

Potential benefits of the minimal invasive approach include shorter ventilation times and ICU stays, less pain and bleeding, faster recovery, and a better cosmetic result [29].

In the near future, this operation may become the gold standard for MV surgery.

As with all new technologies, a learning curve has to be overcome and a structured training is considered essential for the procedural success. This includes a principal understanding of the mitral valve pathology and repair techniques. A team approach is crucial for success.

After overcoming the initial learning curve this procedure is limited only by massive calcification of the mitral annulus. All other mitral valve pathologies are suitable for this access.

# Valve XS

## References

1. Braunberger E, Deloche A, Berrei A, Abdallah F, Celestin JA, Meimoun P, Chatellier G, Chauvaud S, Fabiani JN, Carpentier A. Very long-term results (more than 20 years) of valve repair with Carpentier's techniques in nonrheumatic mitral valve insufficiency. *Circulation* 2001;104:18–111.
2. David TE, Ivanov J, Armstrong S, Christie D, Rakowski H. A comparison of outcomes of mitral valve repair for degenerative disease with posterior, anterior, and BL prolapse. *J Thorac Cardiovasc Surg* 2005;130: 1242–1249.
3. Gillinov AM, Cosgrove DM, Blackstone EH, Diaz R, Arnold JH, Lytle BW, Smedira NG, Sabik JF, McCarthy PM, Loop FD. Durability of mitral valve repair for degenerative disease. *J Thorac Cardiovasc Surg* 1998;116:734–743.
4. Seeburger J, Borger MA, Doll N, Walther T, Passage J, Falk V, Mohr FW. Comparison of outcomes of minimally invasive mitral valve surgery for posterior, anterior, and bileaflet prolapse. *Eur J Cardiothorac Surg* 2009;36:532–538.
5. Mohty D, Orszulak TA, Schaff HV, Avierinos JF, Tajik JA, Enriquez-Sarano M. Very long-term survival and durability of mitral repair for mitral valve prolapse. *Circulation* 2001;104:11–17.
6. Enriquez-Sarano M, Akins CW, Vahanian A. Mitral regurgitation. *Lancet* 2009;373:1382–1394.
7. American College of Cardiology, American Heart Association Task Force on Practice Guidelines (Writing Committee to revise the 1998 guidelines for the management of patients with valvular heart disease), Society of Cardiovascular Anesthesiologists, Bonow RO, Carabello BA, Chatterjee K, de Leon AC Jr, Faxon DP, Freed MD, Gaasch WH, Lytle BW, Nishimura RA, O'Gara PT, O'Rourke RA, Otto CM, Shah PM, Shanewise JS, Smith SC Jr, Jacobs AK, Adams CD, Anderson JL, Antman EM, Fuster V, Halperin JL, Hiratzka LF, Hunt SA, Lytle BW, Nishimura R, Page RL, Riegel B. ACC/AHA 2006 guidelines for the management of patients with valvular heart disease: a report of the American College of Cardiology/ American Heart Association Task Force on Practice Guidelines (Writing Committee to revise the 1998 guidelines for the management of patients with valvular heart disease) developed in collaboration with the Society of Cardiovascular Anesthesiologists endorsed by the Society for Cardiovascular Angiography and Interventions and the Society of Thoracic Surgeons. *J Am Coll Cardiol* 2006;48: 1–148.
8. Seeburger J, Borger MA, Falk V, Kuntze T, Czesla M, Doll N, Ender J, Mohr FW. Minimal invasive mitral valve repair for mitral regurgitation— results of 1339 consecutive patients. *Eur J Cardiothorac Surg* 2008;34: 760–765.
9. Modi P, Rodriguez E, Hargrove WC III, Hassan A, Szeto WY, Chitwood WR Jr. Minimally invasive video-assisted mitral valve surgery: a 12-year, 2-center experience in 1178 patients. *Thorac Cardiovasc Surg* 2009;137:1481–1487. Published online ahead of print 29 March 2009.
10. Carpentier A. Cardiac valve surgery — the 'French correction'. *J Thorac Cardiovasc Surg.* 1983;86: 323–337.
11. Anders S, Said S, Schulz F, Puschel K. Mitral valve prolapse syndrome as cause of sudden death in young adults. *Forensic Sci Int.* 2007;171:127–130. doi:10.1016/j.forsciint.2006.10.011.
12. Carabello BA. The current therapy for mitral regurgitation. *J Am Coll Cardiol.* 2008;52:319–326. doi:10.1016/j.jacc.2008.02.084.
13. Rosenhek R, Rader F, Klačar U, Gabriel H, Krejc M, Kalbeck D, Schemper M, Maurer G, Baumgartner H. Outcome of watchful waiting in asymptomatic severe mitral regurgitation. *Circulation.* 2006;113:2238–2244.
14. Fedak PW, McCarthy PM, Bonow RO. Evolving concepts and technologies in mitral valve repair. *Circulation* 2008;117:963–974.
15. Carpentier A. Cardiac valve surgery—the 'French correction'. *J Thorac Cardiovasc Surg* 1983;86:323–337.

16. Maisano F, Torracca L, Oppizzi M, Stefano PL, D'Addario G, La Canna G, Zogno M, Alfieri O. The edge-to-edge technique: a simplified method to correct mitral insufficiency. *Eur J Cardiothorac Surg* 1998;13:240–245.
17. Dreyfus GD, Bahrami T, Alayle N, Mihealainu S, Dubois C, De Lentdecker P. Repair of anterior leaflet prolapse by papillary muscle repositioning: a new surgical option. *Ann Thorac Surg* 2001; 71:1464–1470.
18. Oppell UO, Mohr FW. Chordal replacement for both minimally invasive and conventional mitral valve surgery using premeasured Gore-Tex loops. *Ann Thorac Surg* 2000;70:2166–2168.
19. David TE. Artificial chordae. *Semin Thorac Cardiovasc Surg* 2004;16: 161–168.
20. Frater RW, Vetter HO, Zussa C, Dahm M. Chordal replacement in mitral valve repair. *Circulation* 1990;82:IV125–IV130.
21. Rankin JS, Binford RS, Johnston TS, Matthews JT, Alfery DD, McRae AT, Brunsting LA III. A new mitral valve repair strategy for hypertrophic obstructive cardiomyopathy. *J Heart Valve Dis* 2008; 17:642–647.
22. Chu MW, Gersch KA, Rodriguez E, Nifong LW, Chitwood WR Jr. Robotic 'haircut' mitral valve repair: posterior leaflet-plasty. *Ann Thorac Surg* 2008;85:1460–1462.
23. Casselman FP, La Meir M, Jeanmart H, Mazzarro E, Coddens J, Van Praet F, Wellens F, Vermeulen Y, Vanermen H. Endoscopic mitral and tricuspid valve surgery after previous cardiac surgery. *Circulation* 2007;116:1270–1275.
24. Bolling SF, Pagani FD, Deeb GM, Bach DS. Intermediate-term outcome of mitral reconstruction in cardiomyopathy. *J Thorac Cardiovasc Surg* 1998;115:381–388.
25. Maisano F, Caldarola A, Blasio A, De Bonis M, La Canna G, Alfieri O. Midterm results of edge-to-edge mitral valve repair without annuloplasty. *J Thorac Cardiovasc Surg* 2003;126:1987–1997.
26. Langer F, Schäfers HJ. RING plus STRING: papillary muscle repositioning as an adjunctive repair technique for ischemic mitral regurgitation. *J Thorac Cardiovasc Surg* 2007;133:247–249.
27. Langer F, Rodriguez F, Cheng A, Ortiz S, Nguyen TC, Zasio MK, Liang D, Daughters GT, Ingels NB, Miller DC. Posterior mitral leaflet extension: an adjunctive repair option for ischemic mitral regurgitation? *J Thorac Cardiovasc Surg* 2006;131:868–877.
28. Borger MA, Murphy PM, Alam A, Fazel S, Maganti M, Armstrong S, Rao V, David TE. Initial results of the chordal-cutting operation for ischemic mitral regurgitation. *J Thorac Cardiovasc Surg* 2007;133: 1483–1492.
29. Seeburger J, Borger MA, Falk V, Passage J, Walther T, Doll N, Mohr FW. Minimal invasive mitral valve surgery after previous sternotomy— experience in 181 patients. *Ann Thorac Surg* 2009;87:709–714.
30. Anyanwu AC, Adams DH. Why do mitral valve repairs fail? *J Am Soc Echocardiogr.* 2009;22: 1265–1268.
31. Gammie JS, Bartlett ST, Griffith BP. Small-incision mitral valve repair: safe, durable, and approaching perfection. *Ann Surg.* 2009;250:409–415.

All rights reserved. Technical alterations are possible. The information provided in this leaflet is distributed by Aesculap, Inc. for educational purposes and not for the purpose of rendering medical advice. The material in this leaflet is not instructional and should NOT be relied upon by surgeons and staff as adequate training for performing the surgeries illustrated. This brochure is intended for health care professionals and employees, not for patients. The information presented is not a substitute for a medical examination and opinion by a licensed physician regarding a patient's diagnosis or recommended course of treatment. This leaflet may be used for no other purposes than offering, buying and selling of our products. No part may be copied or reproduced in any form. In the case of misuse we retain the rights to recall our catalogs and price lists and to take legal actions.

©2012 AESCULAP. ALL RIGHTS RESERVED. PRINTED IN THE USA.  
Aesculap is an equal opportunity employer

Aesculap, Inc. | 3773 Corporate Parkway | Center Valley, PA | 18034  
Phone 800-282-9000 | Fax 610-791-6886 | [www.aesculapusa.com](http://www.aesculapusa.com)

Aesculap, Inc. - a B. Braun company

DOC1017 4M 2/12